

Algirdas Puisys
Tomas Linkevicius

The influence of mucosal tissue thickening on crestal bone stability around bone-level implants. A prospective controlled clinical trial

Authors' affiliations:

Algirdas Puisys, Tomas Linkevicius, Vilnius Mokslo Group, Vilnius, Lithuania
Algirdas Puisys, Tomas Linkevicius, Vilnius Implantology Center, Vilnius, Lithuania
Tomas Linkevicius, Institute of Odontology, Faculty of Medicine, Vilnius University, Vilnius, Lithuania

Corresponding author:

Tomas Linkevicius, DDS, Dip Pros, PhD
Institute of Odontology, Faculty of Medicine, Vilnius University
Zalgirio str. 115/117, LT- 08217, Vilnius, Lithuania
Tel.: +370 687 72840
Fax: +370 527 60725
e-mail: linktomo@gmail.com

Key words: allogenic membrane, biologic width, crestal bone loss, thin mucosal tissues, tissue thickening

Abstract

Objective: To evaluate how bone-level implants maintain crestal bone stability after thickening of thin mucosal tissues with allogenic membrane.

Materials and methods: Ninety-seven bone-level implants of 4.1 mm diameter (Institute Straumann AG, Switzerland) were evaluated in 97 patients (28 men and 69 women, mean age 47.3 ± 1.2 years). According to vertical gingival thickness, patients were assigned into test T1 (thin, 2 mm or less, $n = 33$), test T2 (thin thickened with allogenic membrane, $n = 32$) and control C groups (thick, more than 2 mm, $n = 32$). Implants were placed in posterior mandible in one-stage approach and after integration were restored with single screw-retained metal-ceramic restorations. Radiographic examination was performed after implant placement, 2 months after healing, after prosthetic restoration and after 1-year follow-up. Crestal bone loss was calculated mesially and distally. Mann–Whitney *U*-test was applied and significance was set to 0.05.

Results: After 2 months, implants in group T1 had 0.75 ± 0.11 mm bone loss mesially and 0.73 ± 0.10 mm distally. Implants in group T2 had 0.16 ± 0.06 mm mesially and 0.20 ± 0.06 mm distally. C group implants lost 0.17 ± 0.05 mm mesially and 0.18 ± 0.03 mm distally. Differences between T1/T2, and T1/C were statistically significant ($P = 0.000$) both mesially and distally, while between T2 and C was not significant mesially ($P = 0.861$) and distally ($P = 0.827$). After 1-year follow-up implants in group T1 had 1.22 ± 0.08 mm bone loss mesially and 1.14 ± 0.07 mm distally. Implants in group T2 had 0.24 ± 0.06 mm mesially and 0.19 ± 0.06 mm distally. C group implants lost 0.22 ± 0.06 mm mesially and 0.20 ± 0.06 mm distally. Differences between T1/T2, and T1/C were statistically significant ($P = 0.000$) both mesially and distally, while between T2 and C was not significant mesially ($P = 0.909$) and distally ($P = 0.312$).

Conclusions: Significantly less bone loss can occur around bone-level implants placed in naturally thick mucosal tissues, in comparison with thin biotype. Augmentation of thin soft tissues with allogenic membrane during implant placement could be way to reduce crestal bone loss.

Crestal bone stability remains one of the most debated issues in implant dentistry. It is considered to be important for cortical bone preservation, longevity of short implants and prevention of peri-implant tissues recession, which usually accompanies crestal bone loss (Bengazi et al. 1996; Ekfeldt et al. 2003). Initial vertical mucosal tissue thickness was shown to be one of the factors having impact on bone stability. Berglundh and Lindhe in an animal study demonstrated that if mucosal tissues are thinned to 2 mm or less, there is significantly more crestal bone resorption after healing, compared with implants in thick gingiva (Berglundh & Lindhe 1996).

Linkevicius et al. performed clinical controlled study and confirmed hypothesis suggested in a previous animal experiment. It was found that mucosal tissues of 2 mm or less in thickness may cause bone loss of 1.38 mm, while implants placed in thick tissues had significantly less bone loss of 0.25 mm (Linkevicius et al. 2009). Furthermore, the succeeding pilot study, comparing regular implant/abutment connection implants with platform switching implants have confirmed that distraction of microgap horizontally does not preserve bone in thin tissues (Linkevicius et al. 2010).

Rationally, it can be suggested that thin tissues might be thickened during implant

Date:

Accepted 13 October 2013

To cite this article:

Puisys A, Linkevicius T. The influence of mucosal tissue thickening on crestal bone stability around bone-level implants. A prospective controlled clinical trial. *Clin. Oral Impl. Res.* 26, 2015, 123–129
doi: 10.1111/clr.12301

placement, thus reducing bone resorption after healing and after 1-year follow-up. Palatal connective tissue grafts were usually used for that purpose; however, big morbidity of the patients and prolonged surgical treatment has serious disadvantages, reducing its usage. Therefore, allogenic membranes might be introduced as a material for vertical tissue thickening.

Thus, the aim of this study was to investigate how bone-level implants maintain crestal bone stability after thickening of thin mucosal tissues with allogenic membrane. Null hypothesis was raised that tissue thickening does not have impact of crestal bone levels.

Materials and methods

Subjects for the study were selected among patients in Vilnius Implantology Center Clinic, Vilnius, Lithuania. The protocol for this study was approved by the Vilnius regional ethical committee for biomedical trials (No.158200-07-512-149). Inclusion criteria were: (i) no <18 years of age; (ii) generally healthy patients, no medical contraindication for implant surgery; (iii) missing teeth in lower jaw posterior area; (iv) minimum of 6 mm bone width; (v) healthy soft tissue (BOP < 15%, PI < 15% CPITN < 2); (vi) minimum 2 mm keratinized gingiva buccally and lingually; (vii) no bone augmentation procedures before and during implant placement; (viii) signed informed consent form for participation and permission to use obtained data for research purposes. Patients were excluded if they did not meet inclusion criteria and they additionally had (i) poor oral hygiene; (ii) history of uncontrolled periodontitis; (iii) smoking; (iv) diabetes; (v) alcoholism; (vi) take medication, influencing healing.

Initially, 102 patients fulfilled inclusion criteria and received 105 implants. Later, three patients with three implants were excluded from the study on the basis of refusal to attend follow-up checkups. Five patients received multiple implants; however, only one implant per patient was included into the study to keep patient-based study design. The selection, which one of two implants will be included into analysis, was randomized by envelope drawing. Therefore, the final sample included 97 patients, consisting of 28 men and 69 women. Subjects' average age was 47.3 ± 1.2 ranging from 21 to 65 years at the beginning of the experiment. Patients received a prophylactic dose of 2 g amoxicillin (Ospamox; Biochemie,

Kiel, Germany) 1 h prior to the surgery. After the administration of 4% articaine 40 ml solution (Ubistesin; 3M ESPE, Seefeld, Germany) for local anesthesia, a mid-crestal incision on the center of edentulous ridge was performed. After crestal incision, buccal flap was raised, while lingual part was left not elevated to ensure direct visibility. Vertical tissue thickness was measured with 1.0 mm marked periodontal probe (Hu-Friedy, Chicago, IL, USA) at the bone crest in the center of future implant placement. After measurement, lingual flap was raised to completely expose implant placement site. If vertical tissue thickness was 2 or less mm, tissues were considered as thin (Fig. 1a). If tissue thickness was more than 2 mm, tissues were defined as thick (Fig. 2). Therefore, three groups were formed: T1 test group – implants placed in thin tissues, T2 test group – implants placed in thin tissues and thickened with allogenic membrane simultaneously with implant placement and C, control group – implants placed in naturally thick tissues.

Bone-level implants (Institute Straumann AG, Basel, Switzerland) of 4.1 mm in diameter were placed equally with bone crest in one-stage approach according to manufacturer's recommendations. Allogenic membrane (Tutodent Purous Dermis; Zimmer, Carlsbad, CA, USA) with dimensions of 10 × 20 mm

and 2 mm in thickness was used for vertical thickening of tissues in group T2. For easier manipulation, membrane was treated with sterile saline solution for 10 min. Small perforations were made through membrane surface that healing abutments could be connected to implants (Fig. 1b). After full-thickness flap elevation, membrane was secured over implants directly on bone surface (Fig. 1c) and tissues sutured with 4/0 sutures (Polysorb; USS-DG, Norwalk, CT, USA) (Fig. 1d). Patients were instructed to rinse the operated site with 0.12% chlorhexidine/digluconate (Perio-aid; Dentaaid, Spain) solution twice a day for a week and prescribed 0.5 g of amoxicillin (Ospamox; Biochemie) three times daily for 7 days. For pain control, patients were suggested 400 mg of ibuprofen to be taken as needed. Patients were advised to minimize trauma to the site and advised to clean healing abutments with very soft toothbrush. The sutures were removed 7–10 days after surgery.

After 2 months of healing, metal ceramic restorations with occlusal openings were made by the same technician and cemented with resin cement (iCem, Hereaus Kulzer, Hanau, Germany) on standard abutments in the laboratory (Fig. 3). Then, restorations were screwed to implants and screw access permanently closed with light-cured composite (Gradia Anterior, GC, Tokyo, Japan).

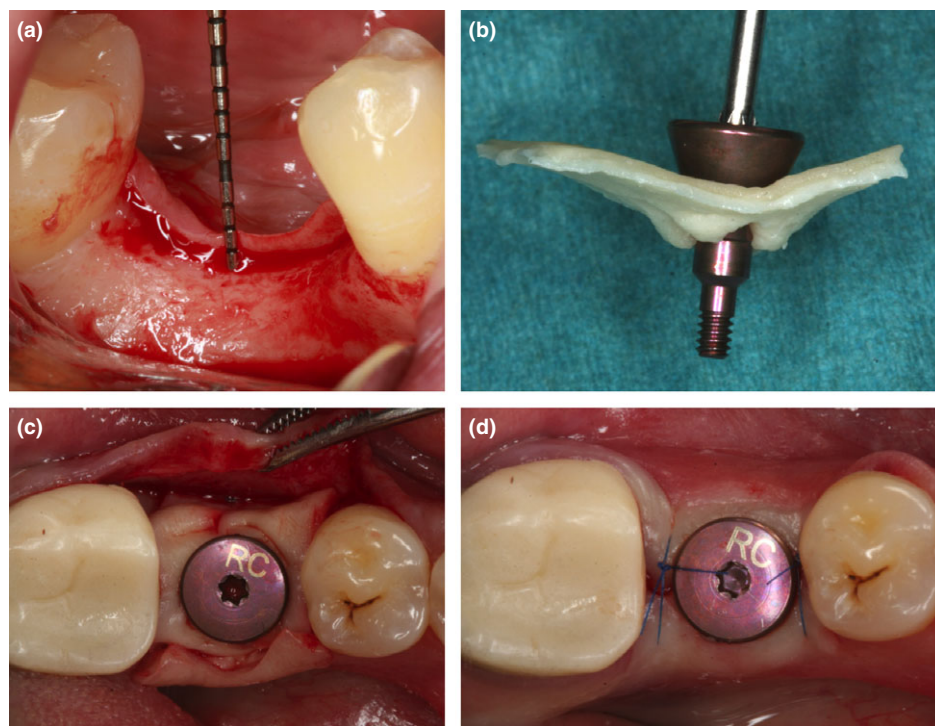


Fig. 1. (a) Thin mucosal tissues before implant placement; (b) Perforated membrane with healing abutment; (c) Allogenic membrane positioned on bone ridge and healing abutment connected to implant; (d) Tissues sutured over membrane and implant at the end of one-stage surgery.

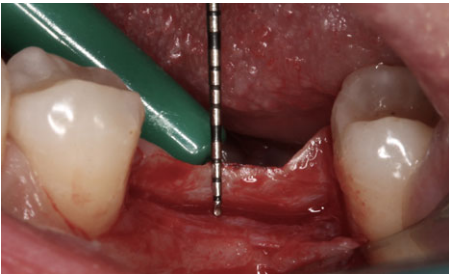


Fig. 2. Vertical measurement of naturally thick mucosal tissues.

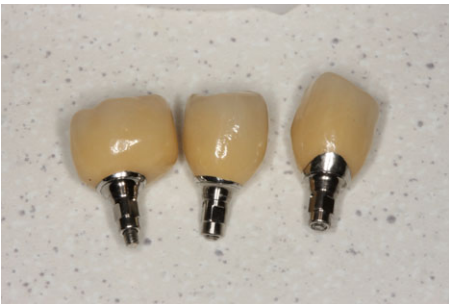

Fig. 3. Metal ceramic restoration cemented on abutment before connection to implant.

Intraoral radiographs were performed four times in each patient during the study: (i) after implant placement and (ii) after 2 months of healing (iii) after prosthetic delivery and (iv) after 1-year follow-up postreconstruction. This was performed for T1 group implants (Fig. 4a–d), T2 group (Fig. 5a–d), and C group (Fig. 6a–d). Paralleling technique with a Rinn-like film holder was used for radiographic examination. The images were obtained in the way that implant/abutment interface, and the threads would be clearly visible to assure that Radiological evaluation and measurements were performed using RVG Windows Trophy 7.0 software (Trophy Radiologie Inc., Paris, France) measurement program with a magnification ($\times 10$) by one examiner. Before calculation of the crestal bone changes, the calibration of RVG images was performed, using calibration program in Trophy RVG software, using implant diameter as a reference point. Bone loss and comparison between groups and within groups was reported separately, on distal and mesial sites. The intra-examiner agreement was determined by second and third measurements, which were performed with 1-month interval. The mean difference between measurements was <0.1 mm, and the mean of three measurements was used.

Data were analyzed using SPSS 15.0 for Windows (SPSS; Chicago, IL, USA) statistical software. The single patient was treated as a statistical unit. Mean bone loss was

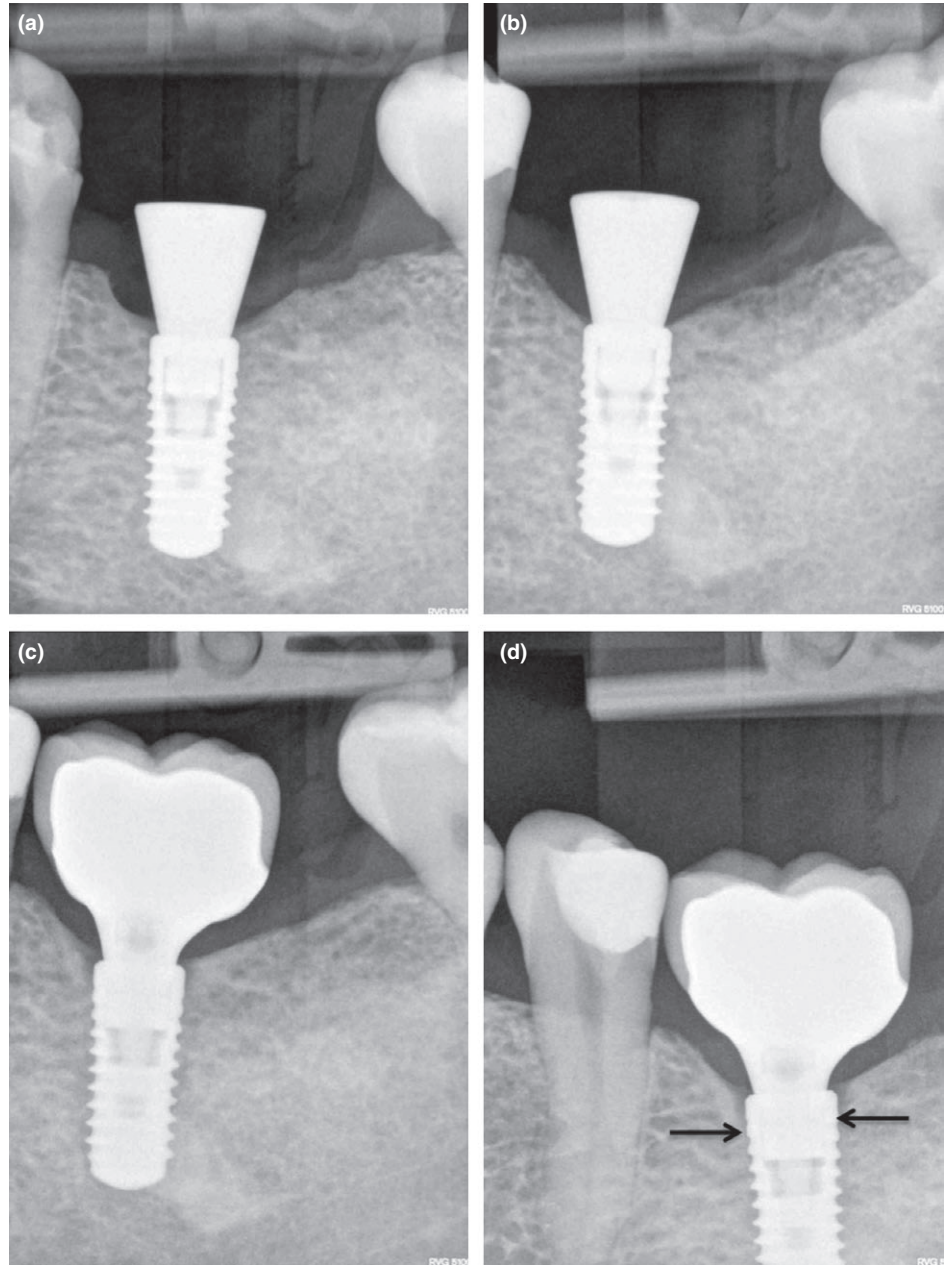


Fig. 4. Crestal bone levels in thin tissues after implant placement (a), 2 months after placement (b), after prosthetic rehabilitation (c) and after 1 year follow-up (d).

calculated for each group with standard error. As variables do not seem to be normally distributed, Mann–Whitney *U*-test was applied to find differences between the groups. The mean differences were considered statistically significant at $P \leq 0.05$ with a confidence interval of 95%. As no data correction of multiple testing was applied, the study should be considered as explorative one.

Results

Ninety-seven bone-level implants with platform switching (Institute Straumann AG)

were included into final sample size. Group T1 received 33 implants, T2 had 32 implants, and 32 implants were placed in control group C. All 97 implants integrated successfully and were restored with 97 cement-retained metal–ceramic restorations. Overall, the implant survival rate after 1 year of function in test and control groups was 100%. No prosthetic complications were recorded at follow-up visits. All 97 allogenic membranes healed uneventfully, no exposures and/or suppuration were registered. Crestal bone loss and statistical significance after 2 months, after prosthetic rehabilitation and

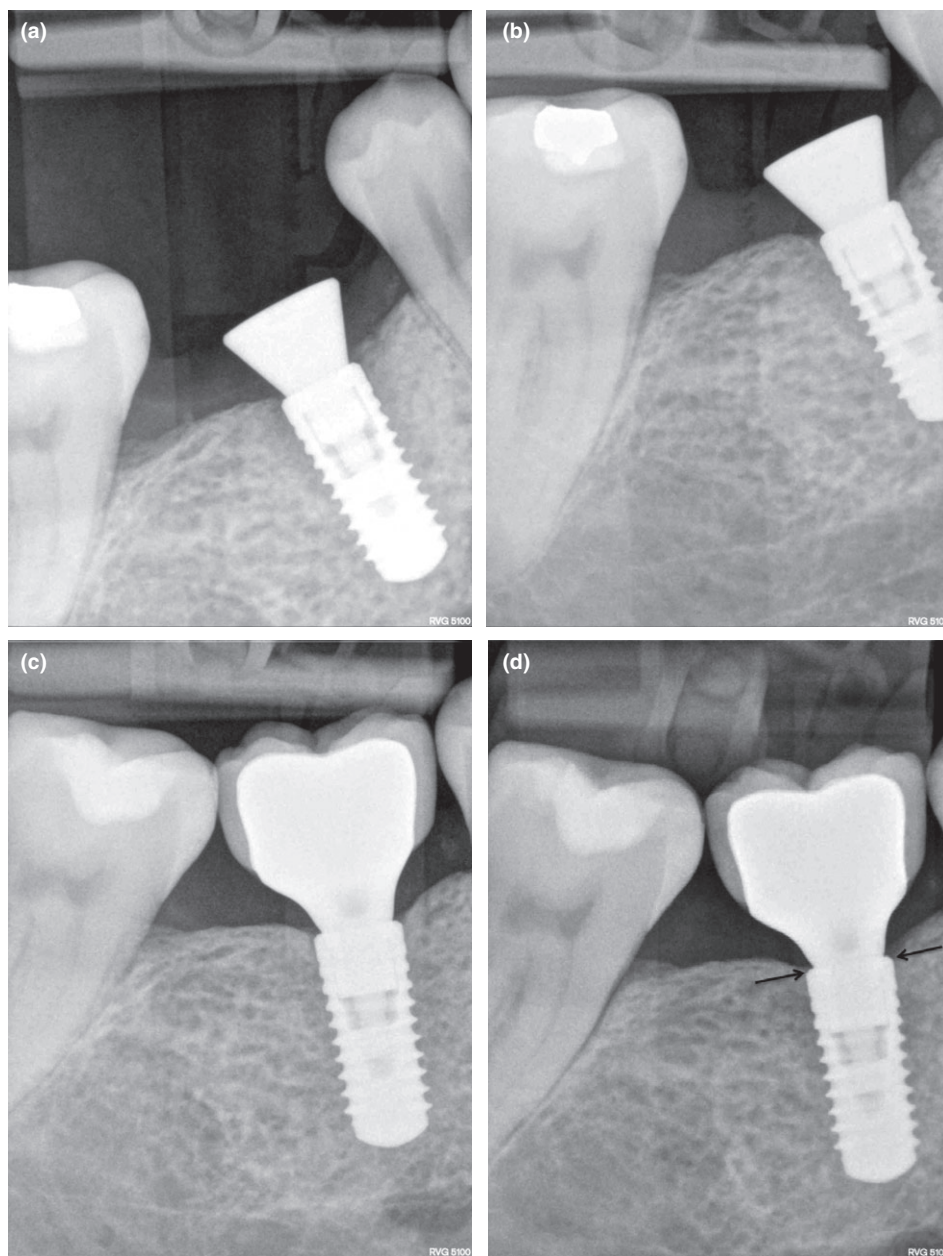


Fig. 5. Crestal bone levels in thickened tissues with allogenic membrane after implant placement (a), 2 months after placement (b), after prosthetic rehabilitation (c) and after 1 year follow-up (d).

after 1-year follow-up can be seen in can be seen in Tables 1–3. Table 4 represents crestal bone loss differences in all groups between period of 2 months after placement and 1-year follow-up.

Discussion

The results of this study showed that implants in group T2 with thin mucosal tissues, which were thickened with allogenic membrane had significantly less crestal bone loss during all measurements, compared with group T1, where thin tissues were not

thickened, and therefore, null hypothesis must be rejected. This is the first clinical study to evaluate the influence of vertical tissue thickening with allogenic membrane on crestal bone stability. Results have confirmed that initial mucosal tissue thickness might be a major factor in crestal bone loss etiology. Implants in control group C with naturally thick soft tissues had the least bone loss, although not significantly less than implants in group T2 with thickened soft tissues. It can be concluded that both soft tissue types – naturally thick and thin, thickened with allogenic membrane do not differ in capability to maintain crestal bone stability

around implants. Conversely, thin soft tissues were not able to keep the bone stable in implants from group T1, thus significant bone remodeling must be expected, if implants are placed in soft tissues of 2 mm or less thickness.

Results of this study are in direct agreement with two preceding studies of Linkevicius et al. (2009, 2010). In 2009, clinical study test implants were placed supracrestally in thin or thick soft tissues, and after 1-year follow-up, implants in thin tissues had 1.35 mm bone loss vs. 0.19 mm of bone remodeling in thick tissues. The study used implants with horizontally matching connection and polished neck, while current study employed bone-level implants with platform switching and roughened-to-the-top implant. However, this difference did not influence the outcome. The second study in 2010 looked at the performance of platform switched implants and regular connection implants in thin soft tissues. It was found that crestal bone loss was evident in both groups, likewise to implants in group T1 with thin soft tissues in the current study. It seems that implant design and surface treatment does not have significant impact on crestal bone levels, if mucosal tissues are thin at the time of implant placement.

The explanation for these results may be found in an animal study by Berglundh & Lindhe (1996). It was suggested that formation of biological width around implants might involve bone loss, if available mucosal tissues are of unsatisfactory thickness. Other studies have found that peri-implant tissues tend to be longer compared with juncto-gingival complex around teeth and make about 3–4 mm (Berglundh et al. 1991; Abrahamsson et al. 1996). Thus, if at the time of the implant placement mucosal tissues do not satisfy minimal requirements, biological width is formed involving bone loss. Similar evidence was presented Oakley et al., who experimented with monkeys to find out how bone reacts to gingival healing after surgical crown lengthening procedures. It was reported that re-establishment of tissue seal involves bone loss around teeth (Oakley et al. 1999).

It is interesting to note that in thin soft tissues bone loss was obvious already at the time of the first measurement – 2 months after implant placement. This time of measurement was chosen according to evidence brought up by Berglundh et al. (2007) experiment. They found that primary immature peri-implant tissue seal forms in 6 weeks after single-stage implant placement or

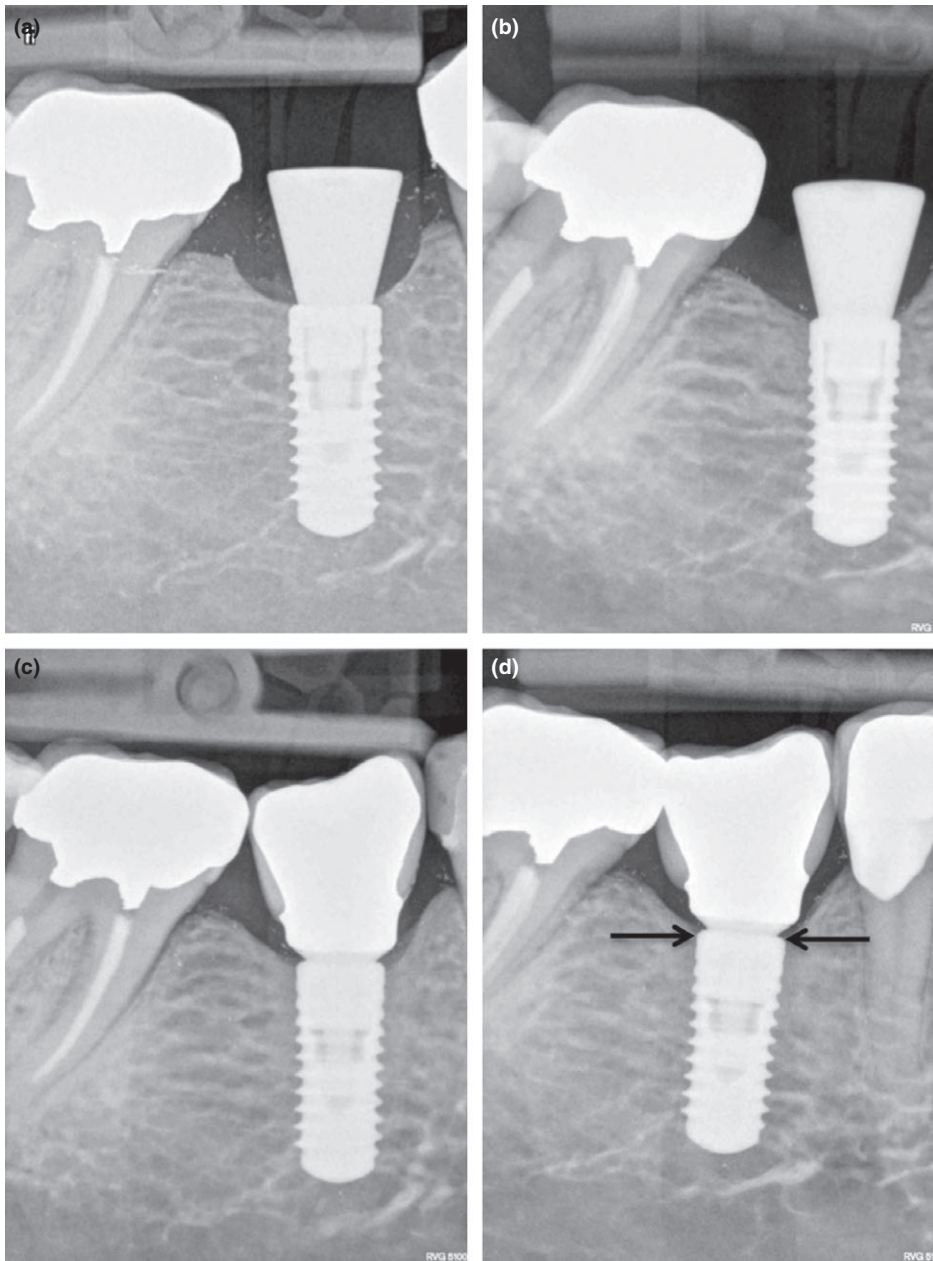


Fig. 6. Crestal bone level after implant placement (a), 2 months after placement (b), after prosthetic rehabilitation (c) and after 1 year follow-up (d) in naturally thick tissue group.

connection of healing abutment in two-stage surgery. Results of the current clinical study suggest that the first radiological signs of biological width formation on bone levels can be seen approximately after 2 months of healing, a way before implant loading. Usually, bone loss before loading is attributed to poor surgical techniques (Toljanic et al. 1999), infection (Esposito et al. 1998) or poor oral hygiene (Tonetti & Schmid 1994). However, new evidence suggests that bone loss before loading might be the consequence of biological width formation, if implants were placed in thin soft tissues. There was an additional bone loss registered in period from 2 months

till 1-year follow-up in all groups. This might be explained that restorative procedures were taking place, involving multiple healing abutment disconnections. It was shown that disruption of the peri-implant seal during abutment unscrewing may also contribute to bone resorption (Abrahamsson et al. 1997). It is possible that maturation of biological width involves bone remodeling with time, as it was showed in this study. Interestingly, major bone remodeling over time occurred in group T1 implants, placed in thin non-augmented tissues and that difference appeared to be statistically significant. It can be hypothesized that biological width around

implants formed from thin mucosal tissues is somehow less stable than peri-implant seal from thick or thickened mucosa.

Vervaeke et al. (2012) in a retrospective clinical study have confirmed that initial tissue thickness has a role in crestal bone remodeling. Authors have studied bone remodeling around implants, restored with prosthetic abutments of a different height for overdenture retention in edentulous mandibles. After observing more bone loss around lower abutments, they assumed that implants with lower abutments, reflecting the initial gingival thickness, lose more peri-implant bone, possibly by a re-establishment of the biological width.

Histologically, allogenic membrane is regenerative tissue matrix donated from bovine with epidermis. This clinical study is the first attempt to use allogenic membrane for vertical thickening of the soft tissues. Previously, it has been used for attached gingiva formation, vestibular or extraction socket augmentation (Cummings et al. 2005; Gapski et al. 2005). Uneventful healing of all 97 allografts, having in mind that augmentation was performed simultaneously with implant placement and healing abutment connection is a promising outcome. Interestingly, membrane was placed under periosteum directly in contact with bone, while usually soft tissue augmentation is performed in the connective tissue component through a split-thickness flap. Full-thickness flap procedure is case of soft tissue thickening has several advantages – surgical procedure is much easier and faster, compared with split-thickness flap approach, therefore less morbidity for the patient. In addition, it is very difficult, or sometimes impossible to make correct split-thickness flap, when soft tissue thickness is 2 mm or less in posterior mandible. Although this may be considered as a novel approach, the results have shown no adverse reactions during healing phase and stable soft tissues after 1-year follow-up. Unfortunately, long-term data of this augmentation approach is still to be established; however, positive short-term results and good outcome of using allogenic membranes for other indications provides a favorable environment to use this method in the future. From the other hand, it is possible that thickened soft tissues may become thinner with time; therefore, this field certainly requires more research.

Wiesner et al. (2010) have performed similar study. They have shown that vertical augmentation of soft tissues is possible with palatal connective tissue grafts and enlargement of 1.3 mm might be expected. Authors

Table 1. Crestal bone loss around implants 2 months after placement and statistical difference between groups (Mann–Whitney *U*-test, significant when $P \leq 0.05$)

Group	Group	Mean ± SE	Median	Maximum	Minimum
T1 (n = 33)	Mesially	-0.75 ± 0.11	-0.70	-0.00	-2.10
	Distally	-0.73 ± 0.10	-0.70	0.00	-1.90
T2 (n = 32)	Mesially	-0.16 ± 0.06	0.00	1.00	-1.00
	Distally	-0.20 ± 0.06	0.00	0.00	-1.30
C (n = 32)	Mesially	-0.17 ± 0.05	0.00	0.00	-1.10
	Distally	-0.17 ± 0.05	0.00	0.00	-1.0

Group	Mesially	Distally
T1 and T2	$P = 0.000$	$P = 0.000$
T2 and C	$P = 0.861$	$P = 0.827$
T1 and C	$P = 0.000$	$P = 0.000$

Table 2. Crestal bone loss around implants after prosthetic restoration and statistical difference between groups (Mann–Whitney *U*-test, significant when $P \leq 0.05$)

Group	Group	Mean ± SE	Median	Maximum	Minimum
T1 (n = 33)	Mesially	-1.00 ± 0.15	-0.85	0.30	-3.70
	Distally	-0.93 ± 0.11	-0.80	0.00	-3.10
T2 (n = 32)	Mesially	-0.25 ± 0.06	-0.05	0.00	-1.00
	Distally	-0.24 ± 0.06	0.00	0.10	-1.10
C (n = 32)	Mesially	-0.22 ± 0.06	0.00	0.00	-1.10
	Distally	-0.19 ± 0.06	-0.05	0.00	-1.00

Group	Mesially	Distally
T1 and T2	$P = 0.000$	$P = 0.000$
T2 and C	$P = 0.734$	$P = 0.987$
T1 and C	$P = 0.000$	$P = 0.000$

Table 3. Crestal bone loss around implants after 1-year follow-up and statistical difference between groups (Mann–Whitney *U*-test, significant when $P \leq 0.05$)

Group	Group	Mean ± SE	Median	Maximum	Minimum
T1 (n = 33)	Mesially	-1.22 ± 0.08	-1.20	-0.10	-2.10
	Distally	-1.14 ± 0.07	-1.20	-0.10	-1.90
T2 (n = 32)	Mesially	-0.24 ± 0.06	0.00	0.00	-1.10
	Distally	-0.19 ± 0.06	0.00	0.00	-1.30
C (n = 32)	Mesially	-0.22 ± 0.06	0.00	0.00	-1.10
	Distally	-0.20 ± 0.06	-0.05	0.00	-1.00

Group	Mesially	Distally
T1 and T2	$P = 0.000$	$P = 0.000$
T2 and C	$P = 0.909$	$P = 0.312$
T1 and C	$P = 0.000$	$P = 0.000$

Table 4. Statistical difference in all groups between period of 2 months after placement and 1-year follow-up (Mann–Whitney *U*-test, significant when $P \leq 0.05$)

	Difference mesially	Difference distally
T1		
After 2 months (n = 33)	-0.75 ± 0.11	-0.73 ± 0.10
After 1 year (n = 33)	-1.22 ± 0.08	-1.14 ± 0.07
<i>P</i> value	0.001	0.001
T2		
After 2 months (n = 32)	-0.16 ± 0.06	-0.20 ± 0.06
After 1 year (n = 32)	-0.24 ± 0.06	-0.20 ± 0.06
<i>P</i> value	0.467	0.955
C		
After 2 months (n = 32)	-0.17 ± 0.05	-0.17 ± 0.05
After 1 year (n = 32)	-0.22 ± 0.06	-0.20 ± 0.06
<i>P</i> value	0.638	0.432

also calculated bone loss around augmented and non-augmented implants; however, there was no statistical difference. This can be explained that in Wiesner et al. study implants with polished collar and with horizontally matching implant/abutment connection were used. Implants were placed at the bone level, thus microgap and polished implant collar were not isolated from the bone. It was shown that polished implant surface and bacteria from microgap are significant factors in crestal bone etiology (Wiskott & Belser 1999; Brogini et al. 2006). Bone-level implants with horizontally shifted microgap allow examining the influence of tissue thickening on crestal bone more properly. Cementless retention was used with the purpose to eliminate cement remnants, as possible reason for bone loss. *In vitro* and clinical studies proved that it is very difficult to completely remove cement after cementation (Agar et al. 1997; Linkevicius et al. 2011, 2013b). It was shown, repeatedly, that remaining cement excess may be the factor for early (Gapski et al. 2008) and delayed peri-implant diseases (Wilson 2009; Linkevicius et al. 2013b).

Conclusions

Within the limitations of this study, it can be concluded that if mucosal tissue are 2 mm or less, significant crestal bone loss might be expected. If tissues are vertically thickened with allogenic membrane during one-stage surgery, crestal bone stability is dramatically increased. Naturally, thick mucosal tissues have very good positive capabilities to keep bone stable, if other factors for bone loss are isolated. It appears that allogenic membrane might be suitable tool to thicken mucosal tissues vertically during one-stage surgery.

References

Abrahamsson, I., Berglundh, T. & Lindhe, J. (1997) The mucosal barrier following abutment dis/reconnection. An experimental study in dogs. *Journal of Clinical Periodontology* **24**: 568–572.

Abrahamsson, I., Berglundh, T., Wennstrom, J. & Lindhe, J. (1996) The peri-implant hard and soft tissues at different implant systems. A comparative study in the dog. *Clinical Oral Implants Research* **7**: 212–219.

Agar, J.R., Cameron, S.M., Hughbanks, J.C. & Parker, M.H. (1997) Cement removal from restorations luted to titanium abutments with simulated subgingival margins. *Journal of Prosthetic Dentistry* **78**: 43–47.

Bengazi, F., Wennstrom, J.L. & Lekholm, U. (1996) Recession of the soft tissue margin at oral

- implants. A 2-year longitudinal prospective study. *Clinical Oral Implants Research* 7: 303–310.
- Berglundh, T., Abrahamsson, I., Welander, M., Lang, N.P. & Lindhe, J. (2007) Morphogenesis of the peri-implant mucosa: an experimental study in dogs. *Clinical Oral Implants Research* 18: 1–8.
- Berglundh, T. & Lindhe, J. (1996) Dimension of the periimplant mucosa. Biological width revisited. *Journal of Clinical Periodontology* 23: 971–973.
- Berglundh, T., Lindhe, J., Ericsson, I., Marinello, C.P., Liljenberg, B. & Thomsen, P. (1991) The soft tissue barrier at implants and teeth. *Clinical Oral Implants Research* 2: 81–90.
- Broggini, N., McManus, L.M., Hermann, J.S., Medina, R., Schenk, R.K., Buser, D. & Cochran, D.L. (2006) Peri-implant inflammation defined by the implant-abutment interface. *Journal of Dental Research* 85: 473–478.
- Cummings, L.C., Kaldahl, W.B. & Allen, E.P. (2005) Histologic evaluation of autogenous connective tissue and acellular dermal matrix grafts in humans. *Journal of Periodontology* 76: 178–186.
- Ekfeldt, A., Eriksson, A. & Johansson, L.A. (2003) Peri-implant mucosal level in patients treated with implant-supported fixed prostheses: a 1-year follow-up study. *International Journal of Prosthodontics* 16: 529–532.
- Esposito, M., Hirsch, J.M., Lekholm, U. & Thomsen, P. (1998) Biological factors contributing to failures of osseointegrated oral implants. (III). Etiopathogenesis. *European Journal of Oral Science* 106: 721–764.
- Gapski, R., Neugeboren, N., Pomeranz, A.Z. & Reissner, M.W. (2008) Endosseous implant failure influenced by crown cementation: a clinical case report. *International Journal of Oral & Maxillofacial Implants* 23: 943–946.
- Gapski, R., Parks, C.A. & Wang, H.L. (2005) Acellular dermal matrix for mucogingival surgery: a meta-analysis. *Journal of Periodontology* 76: 1814–1822.
- Linkevicius, T., Apse, P., Grybauskas, S. & Puisys, A. (2009) The influence of soft tissue thickness on crestal bone changes around implants: a 1-year prospective controlled clinical trial. *International Journal of Oral & Maxillofacial Implants* 24: 712–719.
- Linkevicius, T., Apse, P., Grybauskas, S. & Puisys, A. (2010) Influence of thin mucosal tissues on crestal bone stability around implants with platform switching: a 1-year pilot study. *Journal of Oral & Maxillofacial Surgery* 68: 2272–2277.
- Linkevicius, T., Puisys, A., Vindasiute, E., Linkeviciene, L. & Apse, P. (2013a) Does residual cement around implant-supported restorations cause peri-implant disease? A retrospective case analysis. *Clinical Oral Implants Research* 24: 1179–1184.
- Linkevicius, T., Vindasiute, E., Puisys, A., Linkeviciene, L., Maslova, N. & Puriene, A. (2013b) The influence of the cementation margin position on the amount of undetected cement. A prospective clinical study. *Clinical Oral Implants Research* 24: 71–76.
- Linkevicius, T., Vindasiute, E., Puisys, A. & Peculiene, V. (2011) The influence of margin location on the amount of undetected cement excess after delivery of cement-retained implant restorations. *Clinical Oral Implants Research* 22: 1379–1384.
- Oakley, E., Rhyu, I.C., Karatzas, S., Gandini-Santiago, L., Nevins, M. & Caton, J. (1999) Formation of the biologic width following crown lengthening in nonhuman primates. *International Journal of Periodontics & Restorative Dentistry* 19: 529–541.
- Toljanic, J.A., Banakis, M.L., Willes, L.A. & Graham, L. (1999) Soft tissue exposure of endosseous implants between stage I and stage II surgery as a potential indicator of early crestal bone loss. *International Journal of Oral & Maxillofacial Implants* 14: 436–441.
- Tonetti, M.S. & Schmid, J. (1994) Pathogenesis of implant failures. *Periodontology 2000* 4: 127–138.
- Vervaeke, S., Dierens, M., Besseler, J. & De, B.H. (2012) The Influence of initial soft tissue thickness on peri-implant bone remodeling. *Clinical Implant Dentistry and Related Research*. doi: 10.1111/j.1708-8208.2012.00474.x [Epub ahead of print].
- Wiesner, G., Esposito, M., Worthington, H. & Schlee, M. (2010) Connective tissue grafts for thickening peri-implant tissues at implant placement. One-year results from an explanatory split-mouth randomised controlled clinical trial. *European Journal of Oral Implantology* 3: 27–35.
- Wilson, T.G., Jr. (2009) The positive relationship between excess cement and peri-implant disease: a prospective clinical endoscopic study. *Journal of Periodontology* 80: 1388–1392.
- Wiskott, H.W. & Belser, U.C. (1999) Lack of integration of smooth titanium surfaces: a working hypothesis based on strains generated in the surrounding bone. *Clinical Oral Implants Research* 10: 429–444.